

## Duplex of Upper Extremity Vessels prior to AVF Surgery

OLYMPIC VASCULAR LAB

SURGICAL ASSOCIATES

Chris Griffith MD, James Reus MD, Kevin Robinson MD, Richard Krug MD

Diane Seagroves RVT

MEMORIAL NEPHROLOGY ASSOCIATES

Vo Nguyen MD

Olympia, WA

### PURPOSE:

To assess the patency and suitability of the arteries and veins for use as a dialysis arterio-venous fistula (AVF). The cephalic and basilic veins are preferred AVF conduits for hemodialysis. The patient is usually first referred from the nephrologist to the surgeon for AVF evaluation. After examining the patient, the surgeon selects the preferred extremity for the pre-op mapping study. If suitable vessels are identified, the necessity of performing a bilateral study can be avoided; if suitable vessels are not identified in the preferred extremity, then the contralateral extremity will need to be studied as well.

### INDICATION:

Patients in renal failure who require an arterio-venous fistula for hemodialysis.

### CONTRAINDICATIONS AND LIMITATIONS:

- A. The following conditions limit the areas accessible to the ultrasound beam:
  - 1. Open wound, fresh incision, ulceration, or skin staples
  - 2. Bandages and casts
  - 3. Trauma.
- B. Patient position and inability to move (e.g., surgical procedure, traction, paralysis) may limit ability to perform adequate arm vessel mapping.

### EQUIPMENT AND SUPPLIES

- A. High-resolution B-mode duplex with color flow imager.
- B. Standard supplies for ultrasonic exam: acoustic coupling gel, gloves and skin wipes.
- C. Tourniquet for re-measuring vein size after initial diameter and depth measurements are performed.
- D. Although not absolutely necessary, heating pads and warm room help facilitate the exam and give a more accurate representation of vessel size.
- E. Liquid marking ink (gentian violet) if skin mapping is required.
- F. Pillow(s) or foam pad to position the patient comfortably.
- G. Material for hard copy documentation (i.e. Video tape, PAC, or MO Disc).

### PATIENT PREPARATION:

- A. Explain the procedure to the patient and answer any questions.
- B. Document the pertinent history and appropriate indications.
- C. The patient may be sitting, resting supine with the arms dependent, placed in the reverse Trendelenburg position, or placed in a Trendelenburg position with hands over head. Patient position should be optimized so that gravity helps dilate the veins.
- D. Room and Patient should be warm and comfortable.
- E. A heating pad or hot water bottle can be used (with caution) around the hand during forearm or upper arm imaging or around the forearm during upper arm imaging. The pad temperature should be below 44 C.
- F. After initial measurements (diameter and depth) and especially if the veins are of small size (< 2.5cm, Silva), a tourniquet **MUST ALWAYS** be placed around the upper arm and/or the forearm to dilate the veins and optimize the procedure.
- G. Hand exercise may help dilate the veins.
- H. Tapping the veins may be helpful by inducing reactive dilatation.

## PROCEDURE: GENERAL CONSIDERATIONS:

- A. Before beginning, make sure that both the Vascular Technologist and the patient are comfortable. Complex and small venous systems can take as long as 1 hour to map.
- B. Use enough gel to facilitate visualization.
- C. Marking the skin may not be needed; check with the appropriate physician. During excision, the surgeon usually traces the pathway of the vein under direct vision. Marking may help in cases of unusual anatomy or double channels or for the design of dialysis fistulas. Make sure to keep the probe perpendicular to the surface of the skin so that the line marked on the surface is directly over the vein. Use a short straw or coffee stirrer to mark the skin through the gel. After completing a section, wipe the area dry and mark with gentian violet.
- D. Identify venous branches and follow, if they are large, to their completion to avoid missing variant anatomy.
- E. Location of valve sinuses need not be noted unless stenotic or otherwise abnormal.
- F. Confirm patency of vein with pulsed Doppler or color flow imaging. If any question, position Doppler cursor within segment of vein in question and tap vein distally. Color flow examination may speed the entire examination. This only needs to be done when the vein does not coapt with compression or if there is any question of patency.
- G. The veins should be dilated as much as possible. Gravity, heating, occlusion, tapping, and hand exercise can help. However, stagnant flow forced by the application of a tourniquet may make differentiating vein walls from surrounding tissues difficult.
- H. The diameter and depth of the veins (anteroposterior and/or lateral), measured in a transverse plane without any probe compression, should be noted approximately every 2 inches or when a significant change in size is seen. Vein diameter should be measured without and then with a tourniquet. An increase of vein diameter by 50% with tourniquet is indicative of a suitable vein. If depth of vein is more than 8-10 mm (and depending on diameter of vein), the surgeon will need to consider vein transposition to a more superficial position.
- I. Thrombosed, phlebitic and sclerotic segments of the vein should be noted.
- J. Identification of the length of basilic vein is mandatory. If the basilic vein is too short, it may be unsuitable for transposition.
- K. Detailed identification of branches is not essential; however, identification of the particular variants at the median antecubital fossa is mandatory.

## PROCEDURE: TEST PROTOCOL

**Note:** Although one may choose to perform study distal-to-proximal, this protocol calls for study to be performed proximal (central)-to-distal (peripheral). In this way, if a central venous stenosis is identified at the outset, further exam of the extremity is avoided and attention can be immediately directed to the contralateral extremity.

## VENOUS STUDY

Arm is scanned from proximal to distal, without and then with, tourniquet. If there is a significant proximal arterial or venous narrowing or an abnormality that will jeopardize the success of the AVF, the exam is discontinued. Following the upper arm study, the forearm is studied. Avoid prolonged application of the tourniquet--repeatedly release and re-apply the tourniquet during the study. Essential parameters to be measured include: vessel depth, internal diameter (I.D.) with and without tourniquet, compliance/ability to dilate, continuity with deep system, presence of stenosis/thrombosis, flow rate. Veins should dilate by 50% with use of tourniquet. Veins should be thin walled, vary in size with respiration (the closer to the chest, the greater the variation), collapse completely with compression by transducer and augment with distal compression.

- A. Start at the Internal Jugular vein. Check for patency by identification of flow and changes in vessel size with respiration.
- B. Document flow in both the subclavian artery and vein (arterial flow should be Triphasic). Normal change of the signal during deep Inspiration and Expiration (Respiratory filling of the vein) indicates patency of the Superior Vena Cava.
- C. Locate cephalic vein junction and measure diameter and depth.
- D. Follow the cephalic vein in cross-section with intermittent probe compressions to the antecubital fossa, taking both diameter and depth measurements. Note the presence of, and map, double cephalic systems.
- E. If the upper arm cephalic vein is absent, note if a forearm cephalic vein--upper arm basilic vein connection is present.
- F. Bend arm up and out to expose axilla and confirm patency of axillary artery and vein.
- G. Measure diameter and depth of axillary vein.

- H. Locate the basilic vein as it joins the brachial vein and note length of the basilic vein.
- I. Follow the basilic vein to the antecubital fossa. Repeat same probe compression maneuvers, diameter measurements, and flow determination for the basilic vein. Compression maneuvers to increase flow can be performed manually.
- J. Determine the anatomy of the median antecubital vein and note potential anomalies. Most common:
  - 1. Predominant forearm cephalic upper arm basilic vein
  - 2. Dual upper arm cephalic veins
  - 3. Y-shaped connection between the cephalic and basilic veins
  - 4. Other less common and unusual variations.
- K. Follow the cephalic vein from the antecubital fossa to the "snuffbox" (the hollow depressed area on the radial aspect of the wrist when the thumb is extended fully).
- L. Follow the basilic vein postero-medially in the forearm as far as possible.

## ARTERIAL STUDY

**Note:** This may be accomplished at the same time as the venous portion of the exam.

Standard arterial Doppler protocol should be used, with Doppler angle correct of less than or equal to 60 degrees, and parallel to vessel walls. Measured arterial parameters should include internal diameter, presence of calcifications, thickness/disease of vessel wall, peak systolic velocity (psv) and end-diastolic velocity (edv), pre- and post-reactive hyperemia psv and edv of distal radial and ulnar arteries, flow rate. Doppler-assisted Allen test may be helpful.

- A. Measure internal diameter of arm arteries (brachial & radial) at different levels: ante-cubital, wrist and or any site where a change in size is seen. Optimal internal diameter for AVF is > 2mm (Silva)
- B. Document any arterial calcification or stenosis. A small calcified vessel may be determined by the surgeon to be unusable.
- C. Reactive Hyperemic maneuvers can be used to help determine whether a borderline artery will function. Have patient clench fist for about 60 sec. Reactive Hyperemia is induced with opening of the clenched fist. This maneuver should change a triphasic high-resistance flow to a bi-phasic low-resistance flow. The same reaction is expected after AVF creation when the peripheral resistance in the artery is suddenly decreased after arterio-venous anastomosis. A positive reactive hyperemia maneuver indicates good arterial function post-AVF placement.

## DOCUMENTATION:

- A. Document representative diameters of the veins on hard copy, MO Disc, videotape or other forms of image acquisition.
- B. A drawing of the arm veins that can be taken to the operating room should document:
  - 1. Venous diameters and depth (first without tourniquet) from the Internal Jugular to the wrist
  - 2. Venous diameter with a tourniquet around the proximal upper arm.
  - 3. Intermediary measurements according to the lack of uniformity of the vein (significant changes in diameter).
  - 4. All abnormal findings.
  - 5. Overall assessment of venous system and any problems with procedure.
- C. A drawing of the arm arteries that can be taken to the operating room should document the following:
  - 1. Arterial diameters.
  - 2. Presence of plaque, calcification, bifid arteries, aberrant anatomy.
  - 3. Peak systolic velocities ( psv ) and end diastolic velocities ( edv ) from SCA to distal radial and ulnar arteries.
  - 4. Pre- and post-reactive hyperemia at distal radial and ulnar arteries.

## **INTERPRETATION:**

- A. Patent veins greater than 2 mm in diameter usually will result in a fistula greater than 4 mm in diameter. Veins should dilate by at least 50% with use of tourniquet.
- B. Anatomic configuration alone should not be used to interpret an examination as normal or abnormal; also consider venous flow, wall and valve leaflet appearances.
- C. Phasicity with breathing and augmentation with distal compression indicate normal flow.
- D. Lack of flow or diminished augmentation on compression indicate thrombosis and/or obstruction in the same manner as in studies for deep venous thrombosis
- E. Tortuous flow channels suggest recanalization of previous thrombosis
- F. A good vein appears thin-walled and is easily compressible. A poor-quality vein appears thick-walled and has a residue under compression.
- G. If valve leaflets are visualized, they should appear thin and freely moving within the lumen. If the valve leaflet is rigid and fixed, report it as an abnormality.
- H. The interpretation should include specific statements regarding the forearm and upper arm cephalic and basilic veins and comments about anatomic variances.
- I. A copy of the arm vein mapping report, including the drawing of the veins, is sent or given to the referring physician and/or surgeon.
- J. The surgeon should be notified of any serious abnormalities such as vein absence, thrombosis, inadequate length of Basilic vein, or unusual anatomic variants.
- K. A final report is mailed or faxed to the Surgeon and the patient's Nephrologist after medical interpretation and signature. Original copy is filed in the Vascular Lab chart and a copy is also filed in the office chart.

## **CLEANING AND CARE OF EQUIPMENT:**

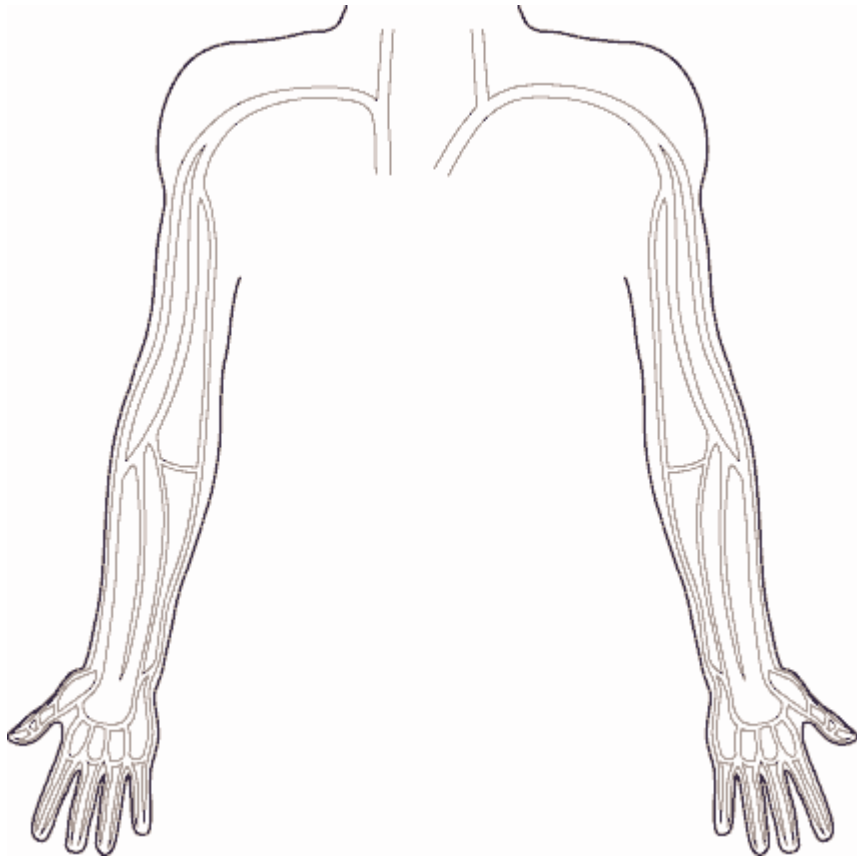
- A. Transducers and equipment are cleaned with appropriate cleaner per the manufacturer.
- B. Heating blankets, tourniquets etc. are wiped clean after use. Alcohol or stronger disinfectant is used as appropriate.
- C. General vascular laboratory routine should be followed as in any other test.

## **REFERENCES:**

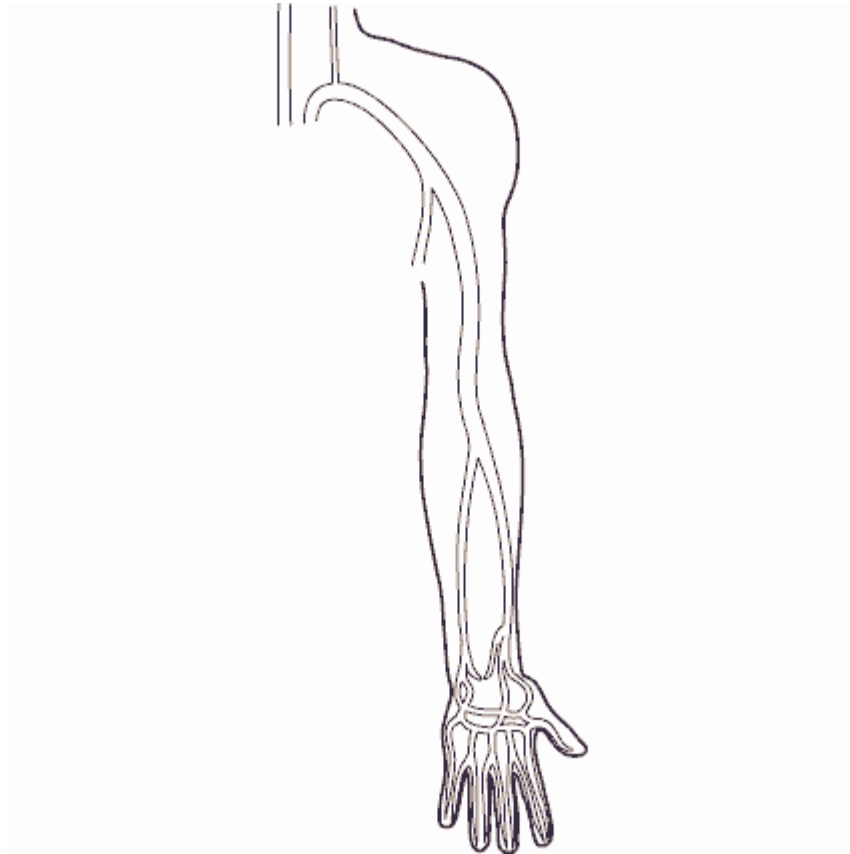
- A. Katz M, Comerota A, DeRojas J: B-mode imaging to determine the suitability of arm veins for primary arteriovenous fistulae. *J Vasc Technol* 11:172-174, 1987.
- B. Salles-Cunha SX, Andros G, Harris RW, et al: Preoperative noninvasive assessment of arm veins to be used as bypass grafts in the lower extremities. *J Vasc Surg* 3:813, 1986.
- C. Seeger JM, Schmidt JH, Flynn TC, et al: Preoperative saphenous and cephalic vein mapping as an adjunct to reconstructive arterial surgery. *Ann Surg* 205,1987.
- D. Roper LD, Maynard MM, Johnson, BL, Bandyk DF, Back MR: Refinements in hemodialysis Access Construction Using a New Protocol for Preoperative Noninvasive Evaluation of the Upper Extremity. *J Vasc Technol* 26(2):83-87, 2002
- E. Comeaux ME, Bryant PS, Harkrider WW: Preoperative Evaluation of the Renal Access Patient with Color Doppler Imaging. *J Vasc Technol* 17(5):247-250, 1993
- F. Malovrh M: The Role of Sonography in the Planning of Arteriovenous Fistulas for Hemodialysis. *Interv. Neph. and Dialysis, Seminars in Dialysis* 16(4):299, July 2003
- G. Silva. A strategy for increasing use of autogenous HD access procedures: Impact of preoperative noninvasive evaluation. *J Vasc Surg* 1998; 27:302-8

(Revised 12/16/03, edited by L. Spergel MD)

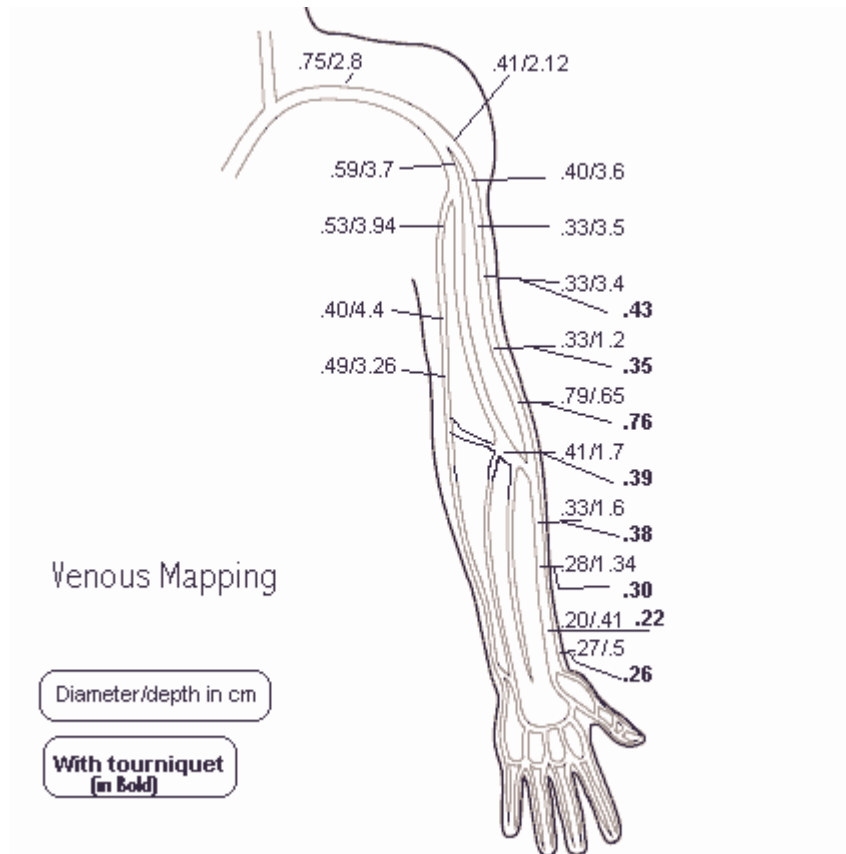
**Venous Template**



## Arterial Template



## Venous Map (example)



# Arterial Map (example)

